IN THE NAME OF GOD

Endoscopic Evaluation of autoimmune bile duct disease : Current and Emerging Techniques

MR FARZANEHFAR,MD

ASSOCIATED PROFESSOR

MUMS

REVIEW

Clin Endosc 2021;54:825-832
https://doi.org/10.5946/ce.2021.048
Print ISSN 2234-2400 • On-line ISSN 2234-2443

Check for updates

CLINICAL ENDOSCOPY

Open Access

Endoscopic Evaluation of Biliary Strictures: Current and Emerging Techniques

Roy Huynh[1,2], Corinne Owers[1], Christopher Pinto[1], Thuy-My Nguyen[1] and Titus Kwok[1]

[1]Department of Upper Gastrointestinal Surgery, Concord Repatriation General Hospital, Sydney, NSW, [2]Faculty of Medicine, University of New South Wales, Sydney, NSW, Australia

CME

ACG Clinical Guideline: Diagnosis and Management of Biliary Strictures

B. Joseph Elmunzer, MD, MSc[1], Jennifer L. Maranki, MD, MSc[2], Victoria Gómez, MD[3], Anna Tavakkoli, MD, MSc[4,5], Bryan G. Sauer, MD, MSc, FACG[6], Berkeley N. Limketkai, MD, PhD, FACG[7], Emily A. Brennan, MLIS[8], Elaine M. Attridge, MLS[9], Tara J. Brigham, MLIS, AHIP[10] and Andrew Y. Wang, MD[6]

Downloaded from http://jou
YQp/llQrt

J Hepatobiliary Pancreat Sci (2019) 26:9–42
DOI: 10.1002/jhbp.596

GUIDELINE

Clinical practice guidelines for IgG4-related sclerosing cholangitis

Terumi Kamisawa · Takahiro Nakazawa · Susumu Tazuma · Yoh Zen · Atsushi Tanaka · Hirotaka Ohara · Takashi Muraki · Kazuo Inui · Dai Inoue · Takayoshi Nishino · Itaru Naitoh · Takao Itoi · Kenji Notohara · Atsushi Kanno · Kensuke Kubota · Kenji Hirano · Hiroyuki Isayama · Kyoko Shimizu · Toshio Tsuyuguchi · Tooru Shimosegawa · Shigeyuki Kawa · Tsutomu Chiba · Kazuichi Okazaki · Hajime Takikawa · Wataru Kimura · Michiaki Unno · Masahiro Yoshida

Review Article

CMJ

www.cmj.ac.kr

Role of Endoscopic Procedures in the Diagnosis of IgG4-Related Pancreatobiliary Disease

Ye-Ji Jung[1], Sung-Hoon Moon[1,2,*], and Myung-Hwan Kim[3]

[1]Department of Internal Medicine, Hallym University Sacred Heart Hospital, Hallym University College of Medicine, Anyang, [2]Institute for Liver and Digestive Diseases, Hallym University, Chuncheon, [3]Department of Internal Medicine, Asan Medical Center, University of Ulsan College of Medicine, Seoul, Korea

Case :

- A 29-year-old medical student presents to the emergency department with progressive jaundice and pruritus for several weeks. He has no other significant medical history aside from seasonal allergies and his physical exam is remarkable for scleral icterus. US=IHDs dilatation and a 9-mm gallbladder polyp. MRCP scan shows a CBD stricture with upstream dilation and irregularity of the intrahepatic bile ducts .ERCP is performed where a biliary sphincterotomy is performed, and a high-grade common bile duct stricture is seen. There is spontaneous drainage of biliary sludge. What is next step?
- A-Balloon dilation B-Placement of a plastic biliary stent
- C-Brushing cytology D-CA19-9 E-IgG4

Biliary Strictures

Benign

Iatrogenic causes
Liver transplant
Trauma induced cholangiopathy
Primary Sclerosing Cholangitis
IgG4 Sclerosing Cholangiopathy
AIDS Cholangiopathy
Choledocholithisis
Recurrent Pyogenic Cholangitis
Mirizzi Syndrome
Chemotherapy induced
Cholangitis
Pancreatitis

Malignant

Cholangiocarcinoma
Pancreatic
adenocarcinoma
Ampullary Carcinoma
Lymphoma

Miscellaneous

Metastases to bile ducts
GB carcinoma/HCC
Inflammatory Pseduotumor
Portal Biliopathy
Type I choledochal cyst

Fixed narrowing of a focal segment of the bile duct resulting in proximal biliary is defined as biliary stricture

CURRENT ENDOSCOPIC TECHNIQUES:

1,2.Endoscopic retrograde cholangiopancreatography

3.Endoscopic ultrasound

4. Contrast-enhanced EUS

5.Intraductal ultrasound

6.Cholangioscopy

1,2.Endoscopic retrograde cholangiopancreatography:

- Endoscopic retrograde cholangiopancreatography (ERCP) remains the most widely used diagnostic approach for the evaluation of biliary strictures.
- Initial evaluation by ERCP allows the precise definition of the location, extent, and morphology of biliary strictures.
- Malignant strictures are usually characterized as being long and irregular with evidence of shouldering.

1. Endoscopic retrograde pancreatography

- AIP shows several characteristic features on endoscopic retrograde pancreatography (ERP) that are useful for differentiating it from pancreatic cancer:
- (1) a long stricture of the main pancreatic duct (>1/3 the length of the whole main pancreatic duct)
- (2) lack of upstream duct dilatation (duct diameter apparent upstream duct dilatation).
- The sensitivity and specificity of ERP for differentiating AIP from pancreatic cancer have been reported to be 33-91% and 80-90%, respectively.
- The reported incidence of Post-ERCP pancreatitis in patients with AIP was low (1.2% in 82 patients), because AIP is under a category of chronic pancreatitis which has a protective effect against ERCP-induced pancreatitis.

1. Endoscopic retrograde pancreatography

- In 2011, ICDC recommended the tailored use of ERP because Asian pancreatobiliary endoscopists had usually performed diagnostic ERP in most patients with suspected AIP while Western endoscopists rarely performed diagnostic ERP.
- Diagnostic ERP could be used in the setting of indeterminate pancreatic parenchymal imaging for AIP or for seronegative AIP without other organ involvement.
- However, Japanese clinical diagnostic criteria for AIP from 2018 stipulate that magnetic resonance cholangiopancreatography (MRCP) can also be used to diagnose AIP, because the quality of MRCP images has improved.
- The diagnostic use of ERP likely will be increasingly supplanted by MRCP.

2. Endoscopic retrograde cholangiography

- Unfortunately, the morphology of strictures is not useful in providing a specific diagnosis, and tissue sampling using either brush cytology or intraductal biopsies is required.
- Brush cytology is more commonly performed because it is easier and associated with fewer complications.
- Conversely, intraductal biopsies provide greater microarchitecture detail, but require sphincterotomy and can be challenging in narrow bile ducts.
- The diagnostic advantage of intraductal biopsies over cytology brushings has also not been demonstrated.

2. Endoscopic retrograde cholangiography

- A meta-analysis performed by Navaneethan et al showed that the pooled sensitivity and specificity of brush cytology in the diagnosis of malignant strictures were 45% (95% confidence interval [CI], 40–50%) and 99% (95% CI, 98–100%), respectively.
- For intraductal biopsies, the pooled sensitivity and specificity were comparable at 48.1% (95% CI, 42.8–53.4%) and 99.2% (95% CI, 97.6–99.8%), respectively.

2. Endoscopic retrograde cholangiography

- Combining the two modalities increased the sensitivity marginally to 59.4% (95% CI, 53.7–64.8%), with a specificity of 100%.
- The poor sensitivity of tissue sampling through ERCP has been attributed to multiple factors, including the effects of desmoplasia in malignancy, which can reduce the yield of samples obtained with brush cytology.

2. Endoscopic retrograde cholangiography

- Furthermore, inflammation secondary to obstruction or infection can cause cellular changes such as hyperplasia or degenerative disfigurements, making it difficult to distinguish between benign and malignant lesions.
- Although the diagnostic yield of tissue sampling is reliant on the morphology of the stricture, other factors including the technical skill of the endoscopist and the interpretative ability of the pathologist remain important factors.
- **Increasing the number of brushings has been shown to improve diagnostic accuracy;** however, stricture dilation or increasing the brush length does not.

2. Endoscopic retrograde cholangiography

- IgG4-SC, which is the bile duct involvement of IgG4-RD, typically presents radiographically as concentric bile duct wall thickening with biliary strictures.
- According to Nakazawa et al., IgG4-SC is classified into four types according to cholangiographic findings:
  - type 1, stenosis only in the lower part of the common bile duct (differential diagnosis: pancreatic cancer, cholangiocarcinoma, and chronic pancreatitis)
  - type 2, stenosis diffusely distributed in the intra- and extra-hepatic bile ducts (differential diagnosis: primary sclerosing cholangitis and secondary sclerosing cholangitis)
  - type 3, stenosis in both hilar and hepatic lesions and the lower part of the common bile duct (differential diagnosis: cholangiocarcinoma and gallbladder cancer)
  - type 4, bile duct strictures only in the hilar hepatic lesions (differential diagnosis: cholangiocarcinoma and gallbladder cancer).

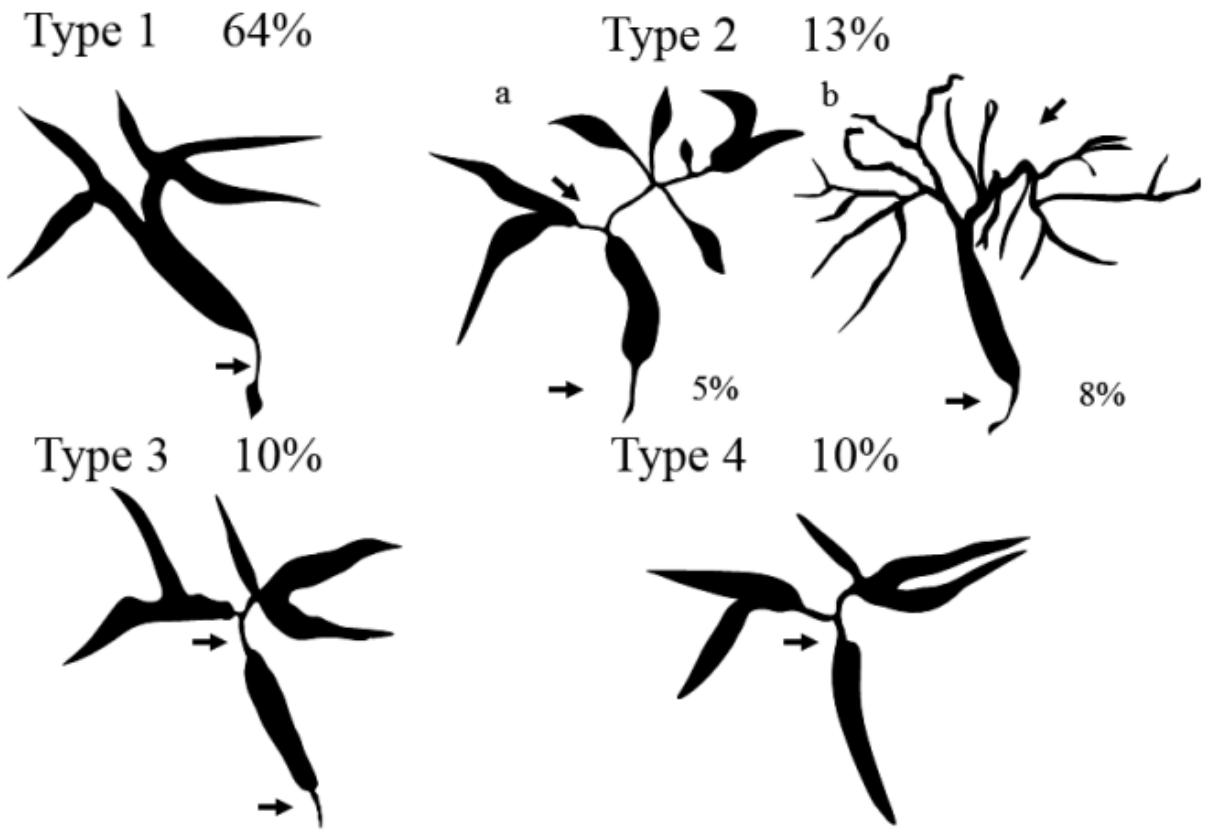

Fig. 1 Cholangiographic classification of IgG4-SC referred from Reference 18

2. Endoscopic retrograde cholangiography

- Type 1 IgG4-SC is usually associated with AIP.
- Isolated type 4 IgG4-SC is especially difficult to differentiate from cholangiocarcinoma.
- For differentiating type 4 pattern from cholangiocarcinoma, mild proximal duct dilatation despite a long stricture with concentric wall thickening is characteristic of IgG4-SC, whereas marked proximal duct dilatation with eccentric wall thickening is characteristic of cholangiocarcinoma.
- State-of-the-art MRCP displays high-resolution images of the pancreatic and biliary ducts, without exposure to invasive intervention or radiation.

2. Endoscopic retrograde cholangiography

- MRCP and endoscopic retrograde cholangiography showed comparable abilities to depict the biliary system to evaluate sclerosing cholangitis.
- Therefore, MRCP can be recommended as an initial modality for evaluating bile ductal abnormalities during the workup for patients with suspected IgG4-SC.
- By contrast, unlike MRCP, ERCP can be used to acquire tissue samples for differentiating cancer and IgG4 immunostaining and to relieve obstructive jaundice.

ERCP:

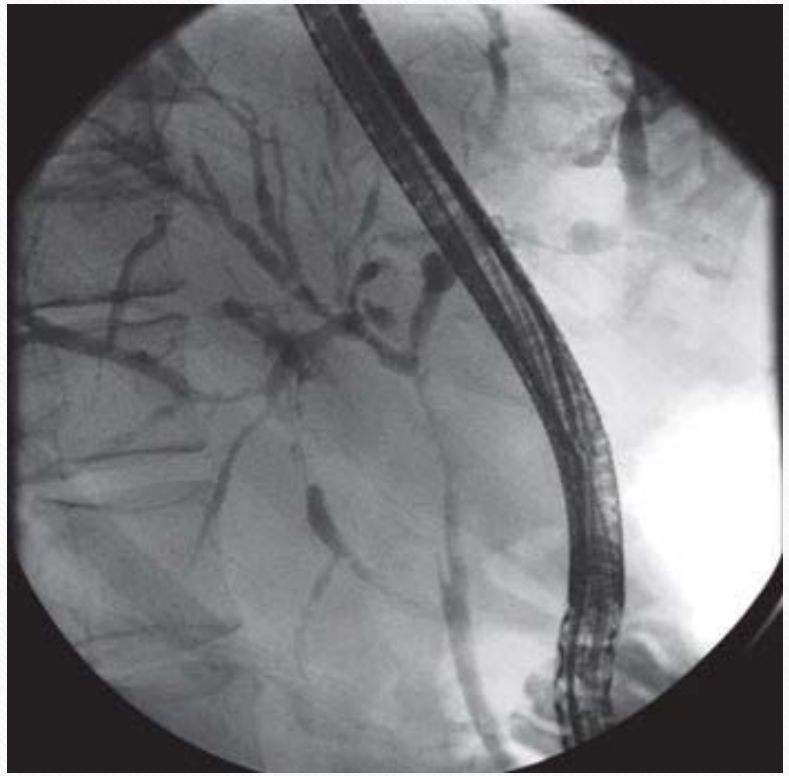

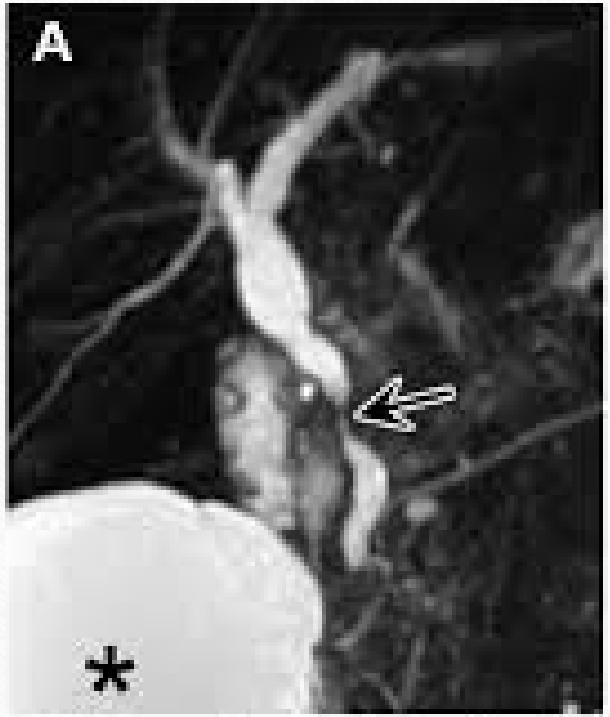





Fig. 1. Endoscopic retrograde cholangiopancreatography image showing severe stenosis in the middle to distal third portion of the common bile duct with associated upstream dilatation.

3.Endoscopic ultrasound:

- Endoscopic ultrasound (EUS) can differentiate between benign and malignant strictures by allowing sonographic visualization of the biliary tract along with the surrounding viscera including the pancreas .

3.Endoscopic ultrasound:

- Further studies on EUS-guided FNA demonstrated improved accuracy when used in conjunction with ERCP and brush cytology.
- A recent meta-analysis by Sadeghi et al.established the pooled sensitivity and specificity of EUS-guided FNA in the diagnosis of malignant biliary strictures to be 80% (95% CI, 74–86%) and 97% (95% CI, 94–99%), respectively.
- When the location of the biliary stricture was taken into consideration, EUS-guided FNA of distal strictures had a higher sensitivity (83% [95% CI, 68–98%]) than that of proximal strictures (76% [95% CI, 66–85%]); however, there was no difference in specificity.

3.Endoscopic ultrasound:

- The practical efficacy of EUS-guided FNA depends on the site, size, and characteristics of the target lesion.
- This has prompted the development of EUS-guided fine-needle biopsy (FNB), which uses a larger needle to obtain core biopsies from the suspected lesion.
- EUS-guided FNB enables obtaining tissue with better integrity and microarchitecture, allowing for innovative biomarker evaluation.

3.Endoscopic ultrasound:

- A recent randomized cross-over trial demonstrated that EUS-guided FNB had considerably higher diagnostic yield and specimen adequacy than FNA.
- The use of EUS-guided FNA and FNB for preoperative diagnosis is currently debatable, with conflicting perspectives published by different governing bodies.
- Given the lack of consolidated evidence, endoscopists should always consider the risk of malignant seeding when performing EUS-guided FNA or FNB, and make their decision on a case-by-case basis.

3.Endoscopic ultrasound:



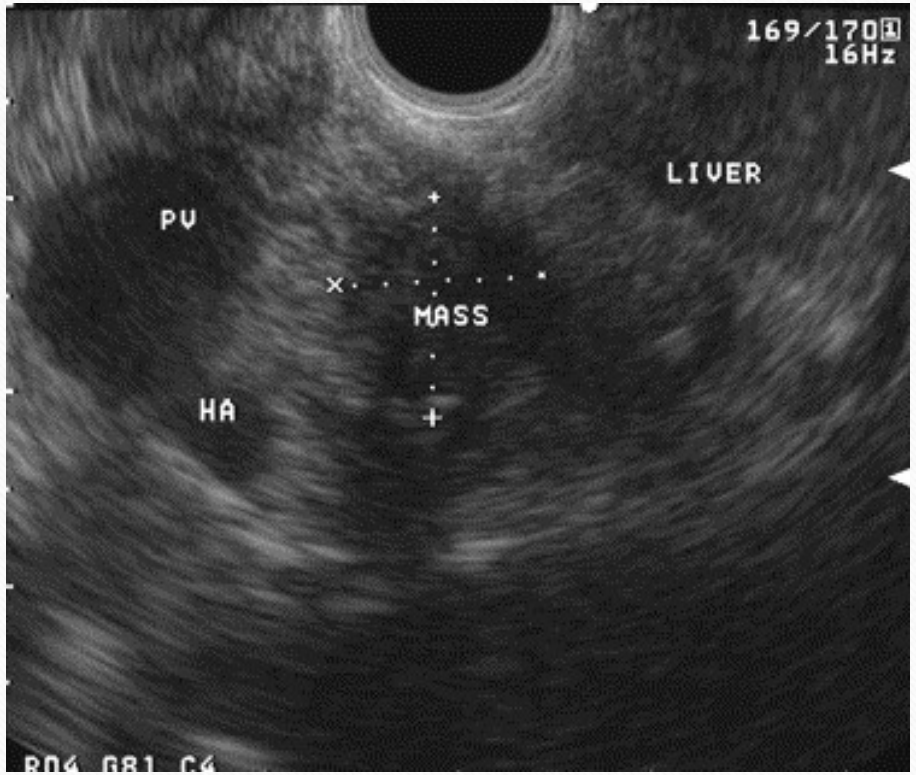

4. Contrast-enhanced EUS

- Contrast-enhanced EUS may differentiate mass-forming AIP from pancreatic cancer because mass-forming AIP typically presents as a psudotumor of hypervascularization, whereas pancreatic cancer is displayed as a hypovascular mass.
- Some researchers have reported high sensitivity (96-100%) and specificity (93-100%) for differentiating AIP from pancreatic cancer by adding quantitative perfusion analysis with the time intensity curve to contrastenhanced EUS.
- A recent study compared 53 patients with pancreatic cancer and 27 with focal AIP.
- The cited study discovered that hyper- to iso-enhancement in the arterial phase, homogeneous contrast agent distribution, and absent irregular internal vessels indicated focal AIP more frequently than pancreatic cancer.

5.Intraductal ultrasound:

- Intraductal ultrasound (IDUS) has been shown to be more accurate than tissue sampling through ERCP in differentiating between benign and malignant biliary strictures.
- Mechanical rotation of the probe permits a cross-sectional view of the bile duct.
- Features suggestive of malignancy include the:
  - Presence of a sessile tumor
  - An interrupted wall structure
  - Tumor size >10 mm.

5.Intraductal ultrasound:

- Tamada et al.demonstrated that if IDUS showed at least two of these features, a malignancy should be considered even if the histologic findings are negative.
- The diagnostic utility of IDUS was assessed by Heinzow et al. in 234 patients with indeterminate biliary strictures. IDUS was diagnostically superior to endoscopic transpapillary biopsies, EUS, and computed tomography in detecting malignant biliary strictures.
- The sensitivity and specificity of IDUS in this study were determined to be 93% (95% CI, 88–97%) and 89% (95% CI, 83–95%), respectively.

5. Intraductal ultrasond

- The appearance of bile duct wall thickening on focused imaging differs between IgG4-SC and cholangiocarcinoma.
- The normal structure of the bile duct on IDUS shows an inner hypoechoic and outer hyperechoic layer.
- The characteristic IDUS findings for IgG4-SC include an even concentric ductal wall thickening with smooth inner and outer margins, whereas cholangiocarcinoma is seen as an uneven eccentric wall thickening with irregular luminal surface and indistinct outer margins.
- According to Naitoh et al.,the most specific IDUS finding for the diagnosis of IgG4-SC was ductal wall thickening of more than 0.8 mm in a non-stenotic area of the bile duct, whereas ductal wall thickening of cholangiocarcinoma was localized in the stenotic area of the bile duct.

5.Intraductal ultrasound:

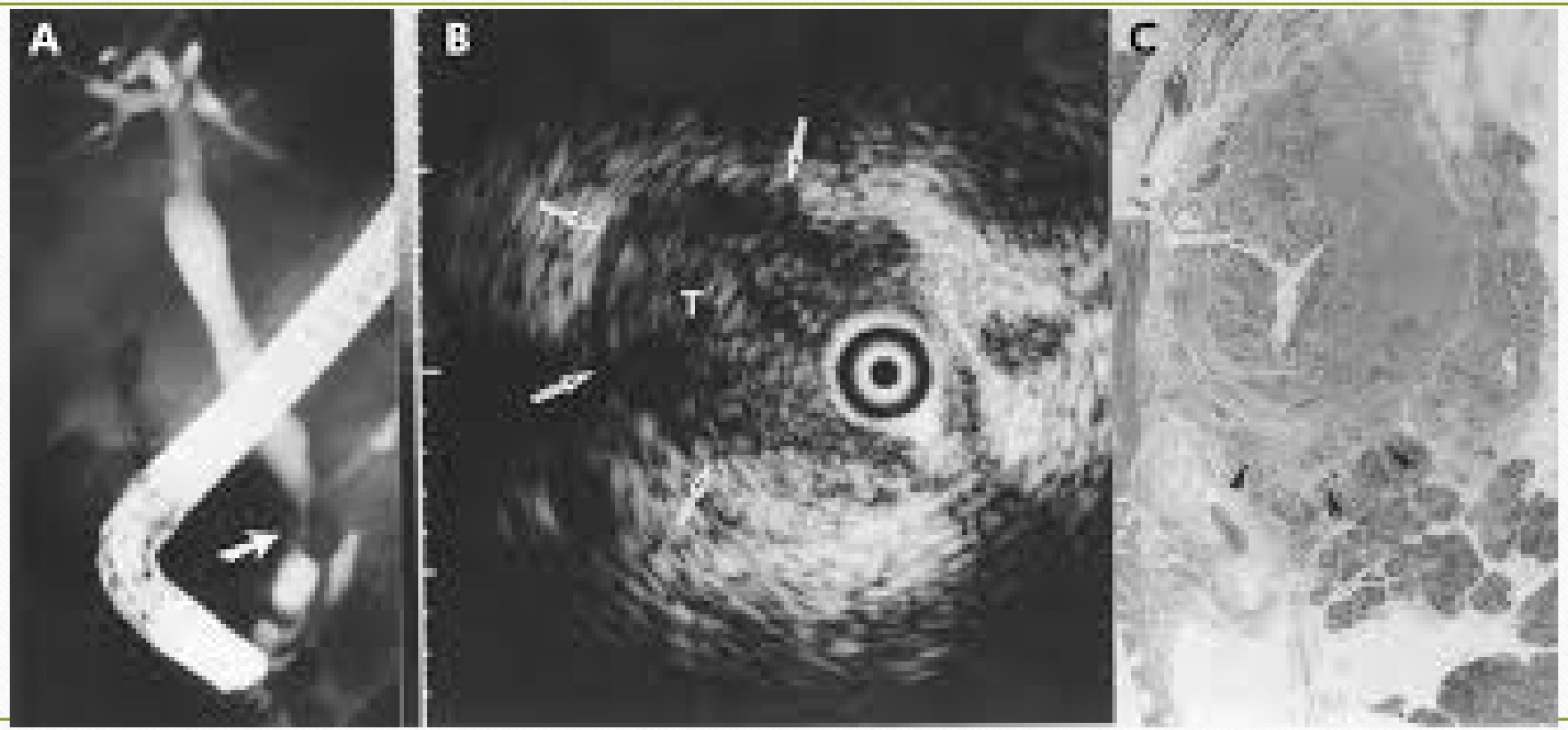

6.Cholangioscopy

- Cholangioscopy can provide direct visualization of the biliary lumen, even though the biliary tree is among the most elusive structures for direct endoscopic evaluation.
- Cholangioscopy may also permit highly targeted biopsy. The most frequent findings on cholangioscopy in patients with IgG4-SC were dilated and tortuous vessels and an absence of partially enlarged vessels.
- Differentiation of IgG4-SC from primary sclerosing cholangitis (PSC) was made based on the finding of significantly higher numbers of dilated and tortuous vessels in IgG4-SC than in PSC, whereas scarring and pseudodiverticula are more frequent in PSC than in IgG4-SC.

6.Cholangioscopy

- Differentiation of IgG4-SC from cholangiocarcinoma was based on a significantly higher incidence of partially enlarged vessels in “distal” cholangiocarcinoma than in IgG4-SC, whereas the incidence of dilated vessels is significantly higher in IgG4-SC than in “hilar” cholangiocarcinoma.
- Although cholangioscopy may be a technically demanding procedure, the recently developed Spy-Glass system and intraductal balloon-guided direct peroral cholangioscopy may overcome the limitations of the current cholangioscopy systems.

Cholangioscopy:



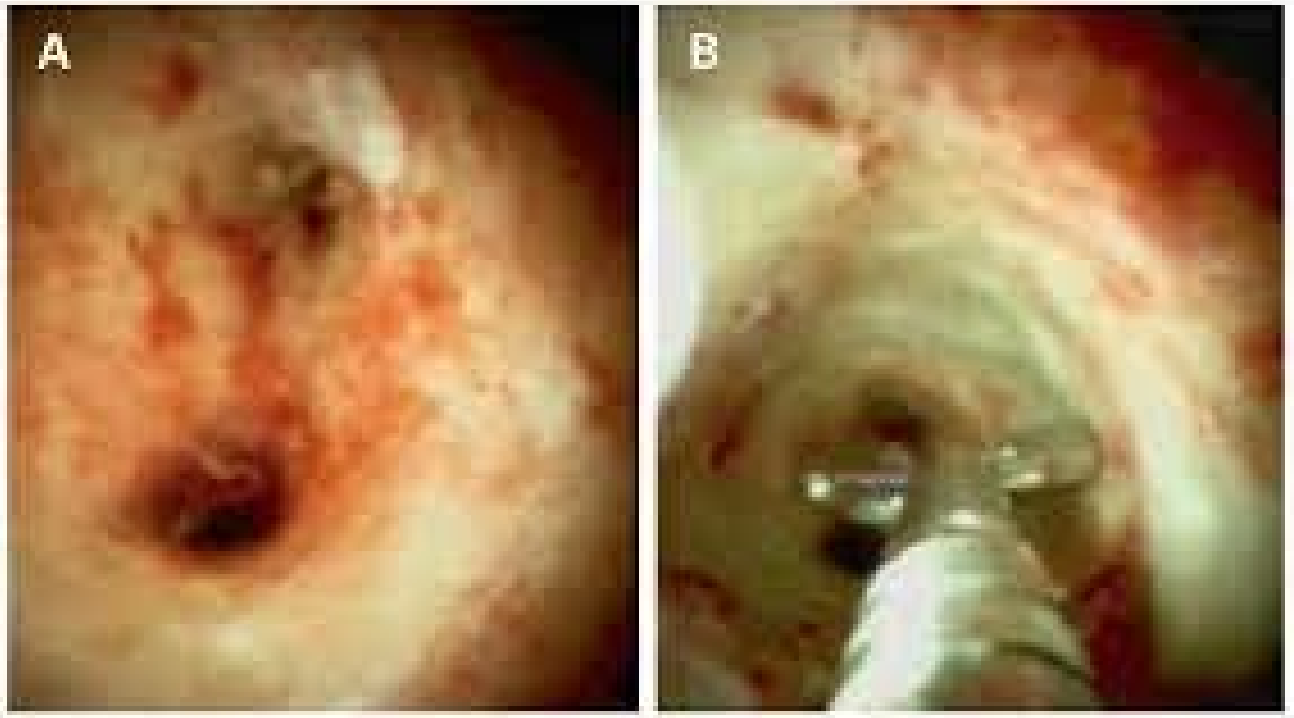

Table 2. Recommendations with associated quality of evidence and strength levels

Recommendation	Quality of evidence	Strength level
1. In patients with an extrahepatic biliary stricture due to an apparent or suspected pancreatic mass, we recommend EUS with fine-needle sampling (aspiration or biopsy) over ERCP as the preferred method of evaluating for malignancy.	Moderate	Strong
2. In patients with an extrahepatic biliary stricture due to an apparent or suspected pancreatic mass, we suggest EUS with FNB or EUS with FNA plus ROSE over FNA without ROSE as the preferred method of evaluating for malignancy.	Very low	Conditional
3. In patients with suspected malignant perihilar stricture, we recommend multimodality sampling over brush cytology alone at the time of the index ERCP.	Low	Strong
4. In patients with an extrahepatic stricture due to a benign condition, we recommend fcSEMS placement over multiple plastic stents in parallel to reduce the number of procedures required for long-term treatment.	Low	Conditional
5. In patients with an extrahepatic stricture due to resectable pancreatic cancer or cholangiocarcinoma, we suggest against routine preoperative biliary drainage. In selected patients, including those with acute cholangitis, severe pruritus, very high serum bilirubin levels, and those undergoing neoadjuvant therapy or experiencing another anticipated delay to surgery, preoperative biliary drainage is warranted.	Low	Conditional
6. In patients with a malignant extrahepatic biliary stricture that is unresectable or borderline resectable, we recommend SEMS placement over plastic stent placement.	Moderate	Strong
7. In patients with a malignant extrahepatic biliary stricture that is unresectable or borderline resectable, the evidence is insufficient to recommend for or against uSEMS vs fcSEMS placement.	Insufficient	
8. In patients with a perihilar stricture due to suspected malignancy, the evidence is insufficient to recommend for or against ERCP vs PTBD.	Insufficient	
9. In patients with malignant perihilar stricture, the evidence is insufficient to recommend for or against PS vs uSEMS placement.	Insufficient	
10. In patients with a malignant perihilar stricture due to cholangiocarcinoma who are not candidates for resection or transplantation, we suggest the use of adjuvant endobiliary ablation (photodynamic therapy or radiofrequency ablation) plus plastic stent placement over plastic stent placement alone.	Low	Conditional
11. In patients with a biliary stricture, in whom ERCP is indicated but unsuccessful or impossible, we suggest EUS-guided biliary access/drainage over PTBD, based on fewer adverse events, when performed by an endoscopist with substantial experience in these interventional EUS procedures.	Very low	Conditional

ERCP, endoscopic retrograde cholangiopancreatography; EUS, endoscopic ultrasound; fcSEMS, fully covered self-expanding metallic stent; FNA, fine-needle aspiration; FNB, fine-needle biopsy; PS, plastic stent; PTBD, percutaneous transhepatic biliary drainage; ROSE, rapid on-site evaluation; SEMS, self-expanding metallic stent; uSEMS, uncovered self-expanding metallic stent

Case :

- A 29-year-old medical student presents to the emergency department with progressive jaundice and pruritus for several weeks. He has no other significant medical history aside from seasonal allergies and his physical exam is remarkable for scleral icterus. US=IHDs dilatation and a 9-mm gallbladder polyp. MRCP scan shows a CBD stricture with upstream dilation and irregularity of the intrahepatic bile ducts .ERCP is performed where a biliary sphincterotomy is performed, and a high-grade common bile duct stricture is seen. There is spontaneous drainage of biliary sludge. What is next step?
- A-Balloon dilation B-Placement of a plastic biliary stent
- C-Brushing cytology D-CA19-9 E-IgG4

EMERGING ENDOSCOPIC TECHNIQUES:

- Confocal laser endomicroscopy
- Optical coherence tomography

Confocal laser endomicroscopy:

- Confocal laser endomicroscopy (CLE) is a promising technique that can provide real-time, in vivo histologic imaging of the bile duct during ERCP.
- The principle of CLE is based on the reflection of focused light through a confocal aperture to provide high-resolution histologic images .
- This technique is performed using a catheter probe that is inserted through the working channel of an endoscope (probe-based CLE) or FNA equipment (needle-based CLE).
- The probe is advanced into the biliary system and the patient is injected with a contrast agent such as fluorescein, which extravasates into the biliary vasculature, highlighting the epithelial and subepithelial structures.

Confocal laser endomicroscopy

- Results from early studies exploring the use of CLE in the diagnosis of biliary strictures suggested an optimistic future.
- In a recent meta-analysis analyzing 12 studies involving 591 patients, Gao et al. determined that the pooled sensitivity and specificity of CLE in discriminating between benign and malignant biliary strictures were 87% (95% CI, 83–91%) and 76% (95% CI, 70–81%), respectively.
- When used in combination with tissue sampling, the sensitivity and specificity increased to 93% (95% CI, 88–96%) and 82% (95% CI, 74–89%), respectively.

Confocal laser endomicroscopy:



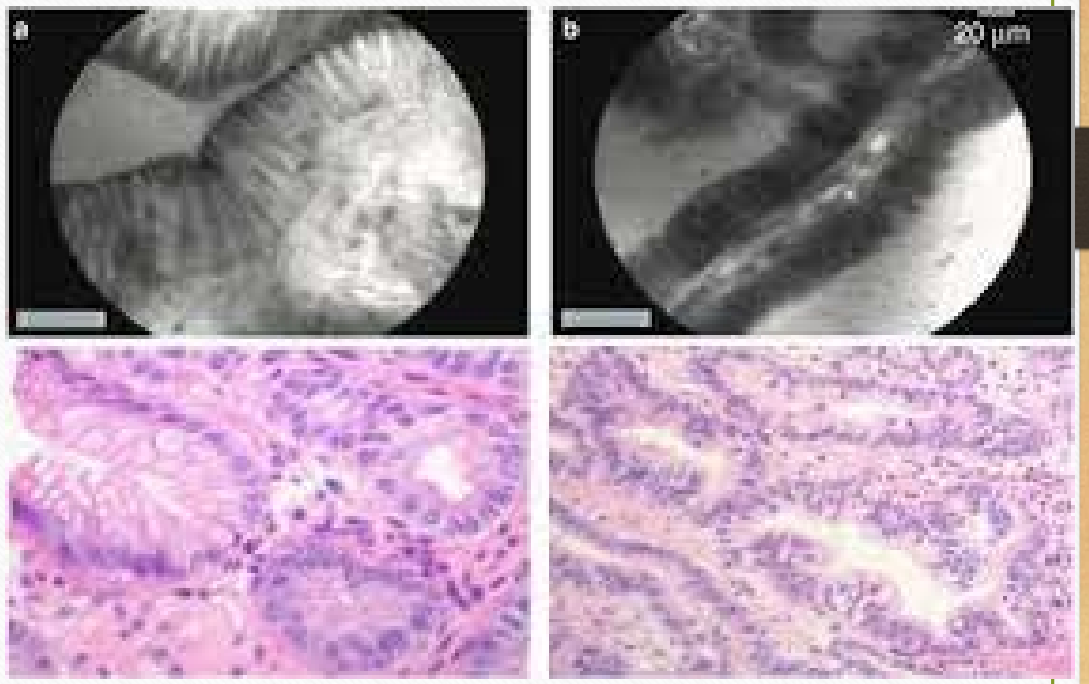

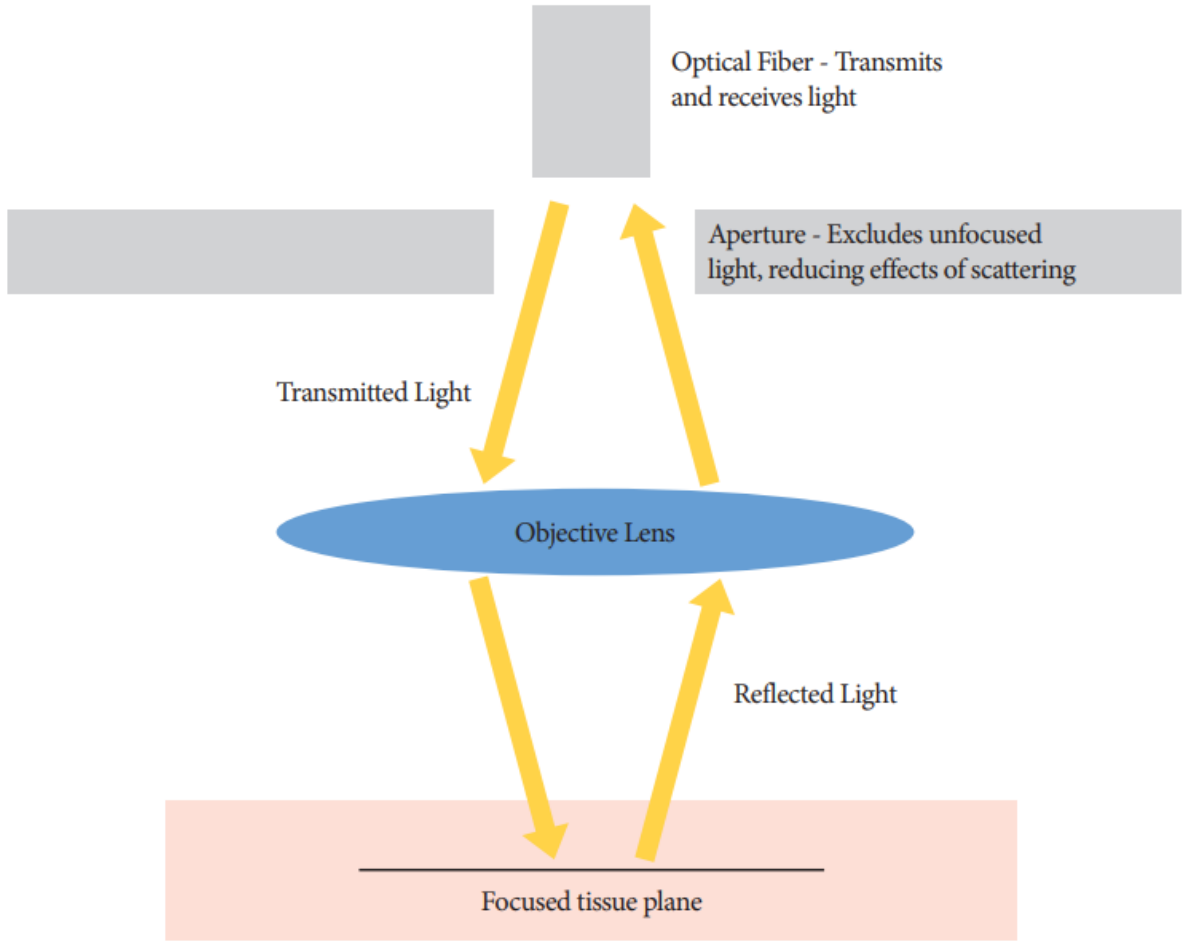

Fig. 3. In confocal laser endomicroscopy, a low-power laser is directed onto a selected horizontal tissue plane and reflected to produce histological images. Out of focus reflected light are filtered out by the aperture, thus producing high-resolution images.

Optical coherence tomography:

- Optical coherence tomography (OCT) enables high-resolution cross-sectional imaging of the biliary tract.
- The principle of OCT is similar to that of B-mode ultrasound, except that it uses infrared light instead of high-frequency sound.
- By measuring the intensity and time delay of backscattered infrared light, cross-sectional images of the biliary tract can be obtained in real time.
- Neoplastic and normal tissues display different light-backscattering patterns, permitting OCT to differentiate between benign and malignant strictures.

Optical coherence tomography:

- The spatial resolution of OCT is almost equivalent to that of histology, allowing clear visualization of the epithelium, fibroconnective submucosa, and acinar tissue as a series of hyperreflective and hyporeflective layers.
- Following ex vivo studies demonstrating that OCT could produce images of the bile duct to a depth of 1 mm, multiple subsequent in vivo studies showed characteristic changes that occur in benign and malignant strictures.
- Arvanitakis et al. evaluated the use of OCT in 37 patients with biliary strictures, and demonstrated that the sensitivity and specificity in detecting malignancy can reach 79% and 100%, respectively, depending on the criteria used.

Optical coherence tomography:

- The relative efficiency of this technique in detecting features suggestive of malignancy has increased its approval among endoscopists.

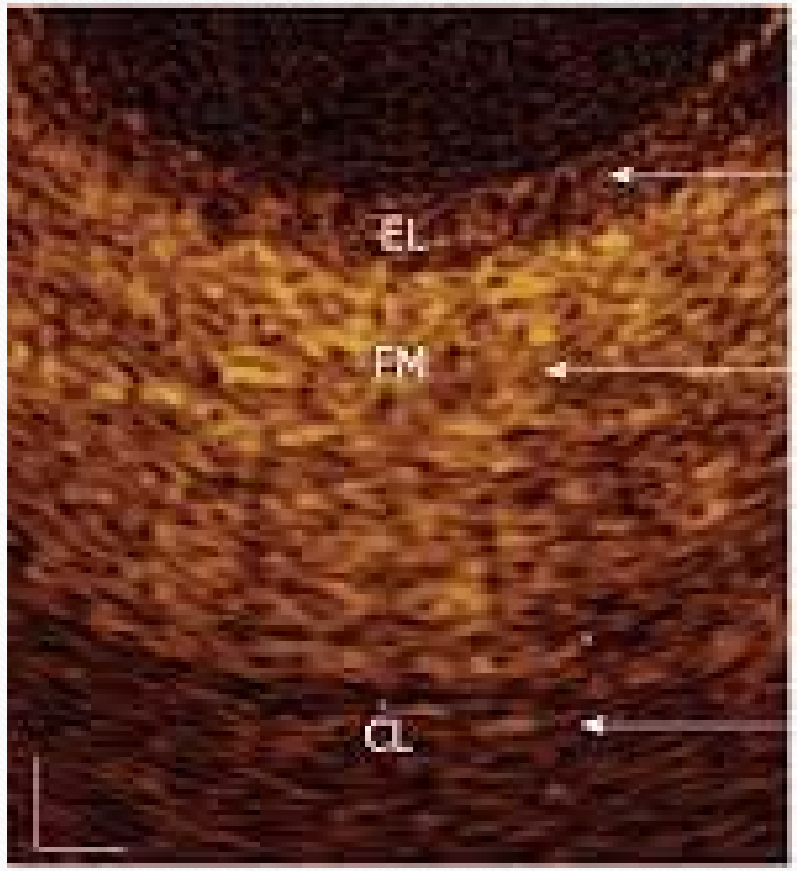
EL
FM
CL


EL
FM
CL

CONCLUSIONS:

- The evaluation of biliary strictures remains challenging despite recent advances in endoscopic techniques.
- The decision to favor one endoscopic approach over another should be individualized; however, the lack of large-scale prospective studies on newer modalities makes this decision difficult.
- The diagnosis of biliary strictures can be aided by developments in cytopathologic staining and imaging practices.
- Thus, a multidisciplinary approach involving endoscopists, surgeons, pathologists, and radiologists is necessary to provide a holistic direction for diagnosis.
- Future advances in endoscopy will undoubtedly improve the detection of malignant biliary strictures.
- In the meantime, clinicians should tailor their decision making to the clinical condition of individual patients when diagnosing biliary strictures.